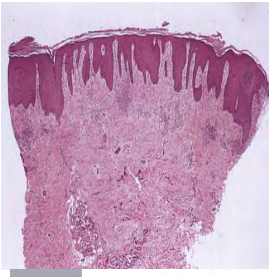

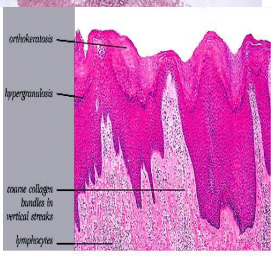
orthokeratosis
hypergranulosis
course collagen bundles in vertical streaks
lymphocytes

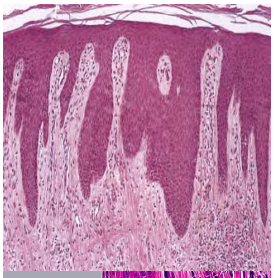

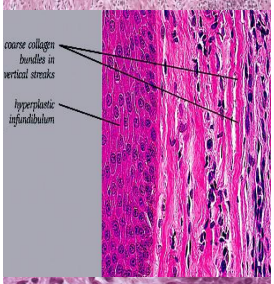
coarse collagen bundles in vertical streaks
hyperplastic infundibulum

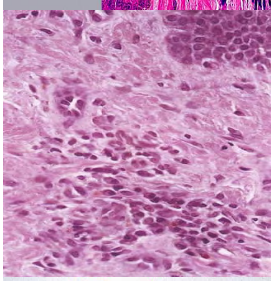

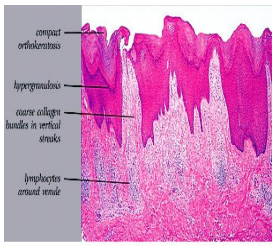

Lichen Simplex Chronicus

The vast majority of patients with pruritus who chronically rub, scratch or pick at *lichen simplex chronicus*. Ironically, the skin may develop macular lichen

Histopathology .

Lichen simplex chronicus is the prototype for chronic dermatitis . There is hyperkeratosis interspersed w

necrotic superficial papillary dermis, fibrin, and neutrophils, are often present; however, they are often pr

exocytosis. In the papillary dermis, there are an increased number of fibroblasts and vertically oriented collagen bundles. As rubbing increases in intensity and chronicity, epidermal hyperplasia becomes more florid and the fibrosis more marked. Searching for features of dermatitis associated with chronic rubbing and scratching may give a hint as to the initial underlying dermatitis.