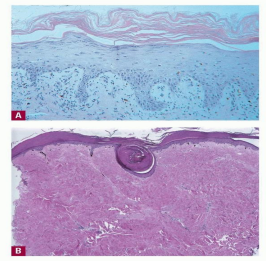

Graft Versus Host Disease

GVHD occurs in situations in which donor immunocompetent T cells transferred into allogenic hosts are

infrequently, unirradiated blood products , solid organ transplants , and matemal-fetallymphocyte engraf

The disease can be divided into an acute and a chronic phase. Acute GVHD typically occurs between 7

In the *acute phase,* the classic triad includes skin lesions, hepatic dysfunctio

In the *chronic phase,* an early lichenoid stage and a late sclerodermoid stage

histopathology

the early changes in the acute phase consist of focal basal vacuolation and sparse superficial

perivascular lymphocytic infiltrate with exocytosis of individual cells into the epidermis and gradual [illegible]

In the *chronic phase,* the early lichenoid stage may still show evidence of sate

In the late sclerodermoid phase, the epidermis is atrophic, with the keratinocytes being small, flattened,

IF Testing. Epithelial basement membrane zone granular IgM and complement deposition i

Pathogenesis.

Acute and chronic forms of the disease have a different pathogenesis. In acute G

The greater the disparity between donor and recipient MHC, the greater the T-cell response. In identical

The inflammatory cytokines (ILs, GM-CSF, TNF-a IFN-y) produced by activated T cells and by tissue da

mechanisms by which the skin, liver, and gastrointestinal tract are targeted are not clear.

Less is understood about the pathophysiology of chronic GVHD. The role of donor T cells against the re

Ultrastructural Study .

The necrotic keratinocytic cytoplasm is filled with numerous aggregated tonofila

Differential Diagnosis.

The acute phase of GVHD is similar to EM, with scattered necrotic keratinocytes and the formation of su

The *eruption* of *lymphocyte recovery* occurs

Distinguishing between the lichenoid lesions of GVHD and lichen planus is often impossible.

However, late sclerotic lesions can be differentiated from scleroderma by the marked atrophy of

the epidermis. Active synthesis of collagen takes place largely in the upper third of the dermis;

in scleroderma, collagen is synthesized mainly in the lower dermis and in the subcutaneous

tissu