**

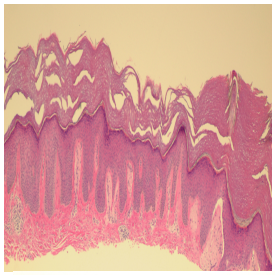

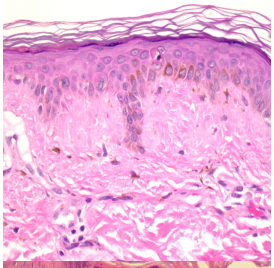

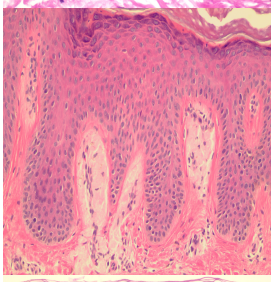

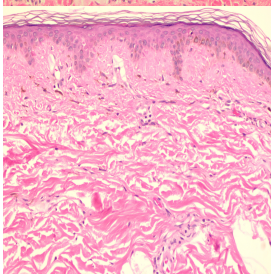

Lichen Amyloidosis and Macular Amyloidosis

Lichen amyloidosis and macular amyloidosis are best considered as different manifestations of the same

Macular amyloidosis is characterized by pruritic macules showing pigmentation with a reticulated or ripp

can be easily passed off as postinflammatory hyperpigmentation by physicians who are unfamiliar with t

Macular amyloidosis and lichen amyloidosis sometimes occur together in the same patient, and lichen a

**

Histopathology .

□ Lichen and macular amyloidosis show deposits of amyloid that are limited to the

In areas in which the entire dermal papilla is filled with amyloid, the amyloid appears homogeneous in bo

the dermal-epidermal junction, they do not stain as amyloid. In addition, there often is a striking degree o

**

Histogenesis .

□ The light microscopic findings in lichen and macular amyloidosis suggest that de

by the cell's own lysosomes. Such digestion produces amyloid filaments. A conversion of tonofilaments

On direct immunofluorescence, all specimens of lichen or macular amyloidosis fluoresce positively for im

The epidermal derivation of the amyloid in lichen and macular amyloidosis is supported by histochemica

After full agreement apparently had been reached about the keratogenic origin of the amyloid in lichen a

The amyloid that may be found in the stroma or in the adjacent connective tissue of basal cell carcinoma and other epithelial tumors has an appearance on electron microscopy and direct immunofluorescence similar to that of lichen and macular amyloidosis, suggesting that it too is

derived from tonofilaments . This amyloid also shows positive staining with antikeratin antiserum