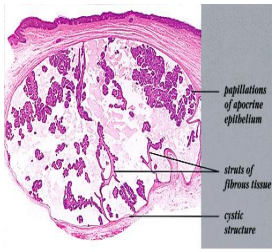
papillations of apocrine epithelium
struts of fibrous tissue
cystic structure

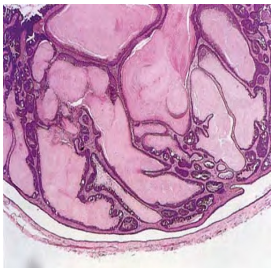

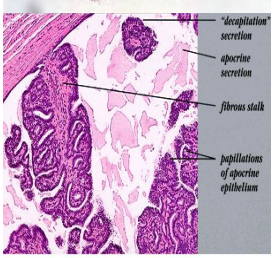
"decapitation" secretion
apocrine secretion
fibrous stalk
papillations of apocrine epithelium

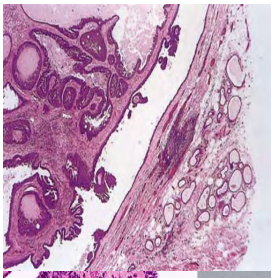

"decapitation" secretion

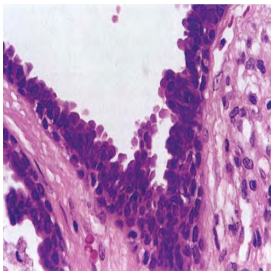

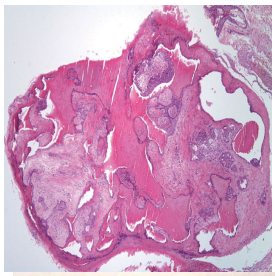

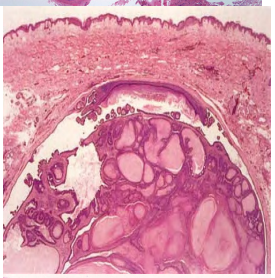

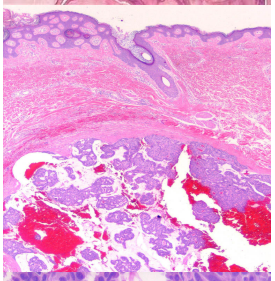

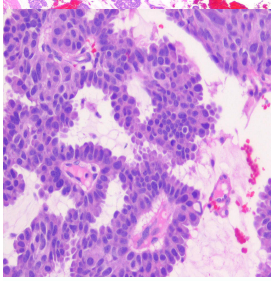

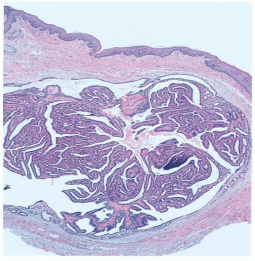

Hidradenoma papilliferum = الحليمي العرقي الغدوم

2 / 2