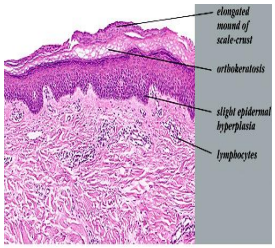

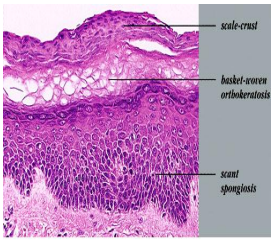

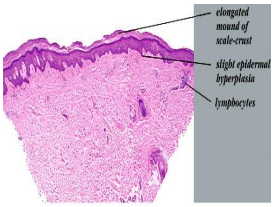

Parapsoriasis

Guttate dermatosis parapsoriasis = نظير الصدف النقطي

There are three entities described as parapsoriasis: small-plaque parapsoriasis, large-plaque parapsoria

Large-plaque parapsoriasis and *parapsoriasis variegata* are best considered as early sta

2 / 8

Guttate dermatosis parapsoriasis = النقطي الصدف نظير

The *small-plaque parapsoriasis* is also known as xanthoerythrodermia perstans of Crock

3 / 8

Guttate dermatosis parapsoriasis = النقطي الصدف نظير

Histopathology .

The small-plaque parapsoriasis shows focal epidermal involvement consisting o

4 / 8

Guttate dermatosis parapsoriasis = النقطي الصدف نظير

Pathogenesis . The inflammatory infiltrate in small-plaque parapsoriasis

T lymphocytes subset. Langerhans cells are increased in the epidermis and dermis .

5 / 8

Guttate dermatosis parapsoriasis = النقطي الصدف نظير

Relationship to Lymphoma

Although it is generally accepted that small-plaque parapsoriasis, or digitate der

6 / 8

Guttate dermatosis parapsoriasis = النقطي الصدف نظير

but conversion into a systemic lymphoma does not occur . However, some believe that small-plaque par

7 / 8

Guttate dermatosis parapsoriasis = نظير الصدف النقطي

8 / 8