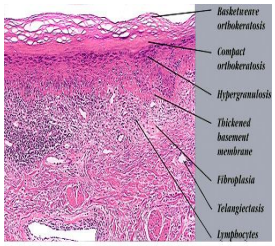

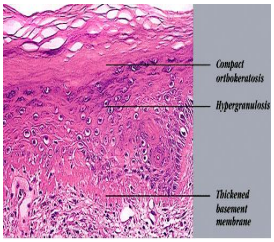

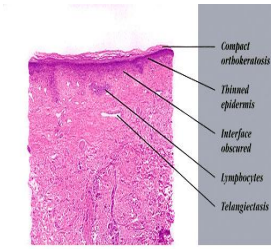

Atrophic discoid lupus erythematosus = - الضمورية القرصية الحمامية الذئبة

Basketweave orthokeratosis
Compact orthokeratosis
Hypergranulosis
Thickened basement membrane
Fibroplasia
Telangiectasis
Lymphocytes

Compact orthokeratosis
Hypergranulosis
Thickened basement membrane

Compact orthokeratosis
Thinned epidermis
Interface obscured
Lymphocytes
Telangiectasis

1 / 1