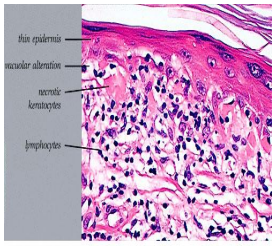

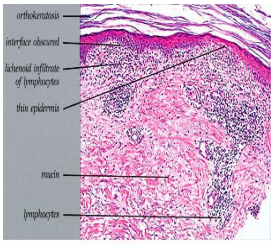

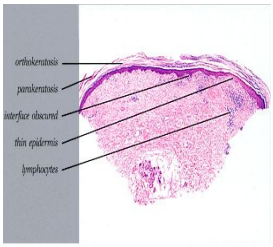

Acute discoid lupus erythematosus = الحادة القرصية الحمامية الذئبة

thin epidermis
vacuolar alteration
necrotic keratocytes
lymphocytes

orthokeratosis
interface obscured
lichenoid infiltrate of lymphocytes
thin epidermis
mucin
lymphocytes

orthokeratosis
parakeratosis
interface obscured
thin epidermis
lymphocytes

1 / 1