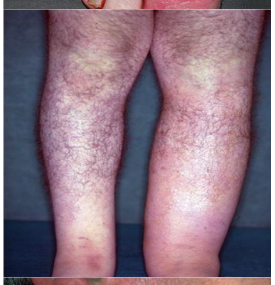

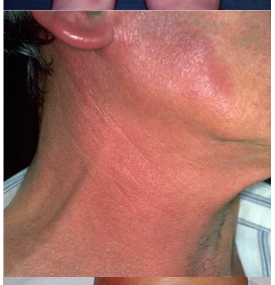

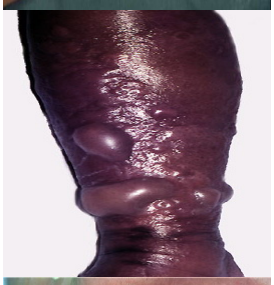
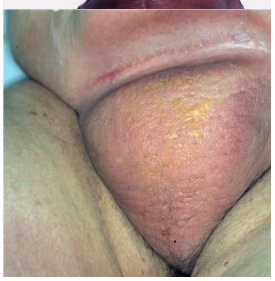

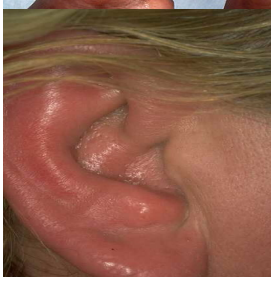

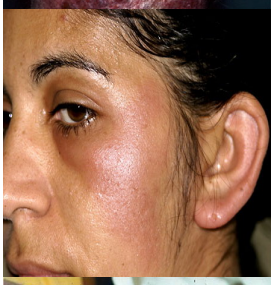

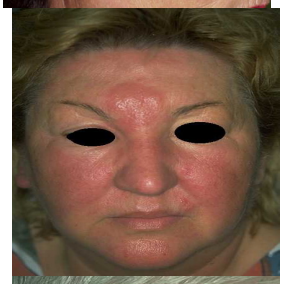

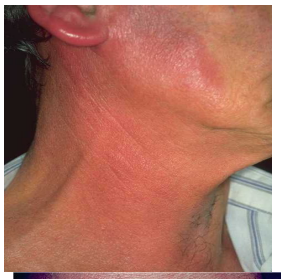

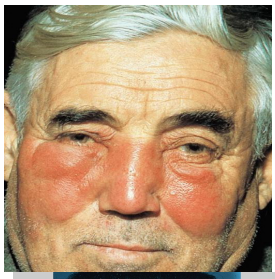

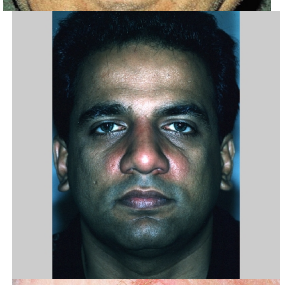

ERYSIPELAS is a distinctive type of superficial cutaneous cellulitis with marked dermal lymphatic involvement characterized by [illegible] *Streptococcus* [illegible] water e[illegible] anaerobic [illegible] gangrene [illegible] infections [illegible] gangrene) [illegible] *Streptococcus* [illegible] gangrene) [illegible] *Clostridium,* [illegible] peptostreptococci [illegible] immunosuppressed [illegible] recurrence, particularly on the lower [illegible] group A streptococcus [illegible] *Pneumo* [illegible] *Bacteroides* [illegible] *Bacteria* [illegible] *Bacteria* [illegible] histotox [illegible] individ [illegible] organisms that o[illegible] the intestine; o[illegible] [illegible] ation a[illegible]