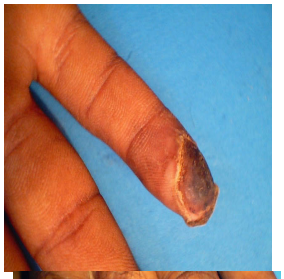

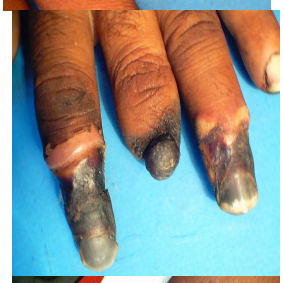

BUERGER DISEASE

THROMBOANGIITIS OBLITERANS

Epidemiology

The prevalence of this disease is greatest in the Mediterranean, the Middle East, and Asia. Males are afflicted with a higher prevalence than females, although an increased incidence in females has occurred in recent years, likely reflecting the pattern of tobacco use. Patients are usually between the ages of 20 and 40 years old. Over the last three decades, there has been a marked decline in the reported prevalence of thromboangiitis obliterans in the United States, possibly reflecting the impact from adoption of strict diagnostic criteria for this disease entity, although declining smoking prevalence may also play a role.

THROMBOANGIITIS OBLITERANS AT A GLANCE

· Rare inflammatory occlusive disease affecting medium and small arteries and veins, most commonly in the extremities.

- Predominantly affects males, age 20 to 40 years old.

- Extremely strong association with smoking; often abates with smoking cessation.

- Clinical manifestations include ischemia, cold sensitivity, or claudication of foot, leg, or hand.

- Ischemic ulcers, peripheral cyanosis, gangrene, or superficial thrombophlebitis.

Etiology and Pathogenesis

The etiology of thromboangiitis obliterans remains unknown. The disease almost exclusively occurs in smokers and often abates with the cessation of tobacco smoking. An increased cellular sensitivity to types I and III collagen has been reported in comparison to a group of normal individuals and patients with atherosclerotic disease. Tissue ischemia is produced by an inflammatory reaction involving medium and small arteries of the extremities and superimposed obstruction by thrombi. Despite the inflammatory process, thromboangiitis obliterans is considered serologically silent, and even during active disease, erythrocyte sedimentation rate and C-reactive protein levels are usually normal. In one report, serum anti-endothelial cell antibody titers were found to be high, and impaired endothelial-dependent vasodilation to acetylcholine has been demonstrated to occur even in non-obstructed limbs. Veins may also be involved. Occasionally, cardiac, intestinal, and cerebral vessels are involved.

Clinical Findings

HISTORY

The most common initial complaints are claudication of the foot or lower calf, digital cyanosis or gangrene, or rest pain. Involvement of multiple limbs is usual. Patients may present with ulcers of the toes or fingers. Although the lower extremities are affected most often, more than one-third of patients have upper-extremity involvement. Ulcerations or gangrenous areas are characteristically extremely painful. Superficial thrombophlebitis, often migratory, may occur in up to 40 percent of patients. Cold sensitivity or even classical Raynaud phenomenon may be observed.

CUTANEOUS FINDINGS

The cutaneous findings of thromboangiitis obliterans are similar

to that of PAD. Common findings include ulceration or gangrene of digits (feet worse than hands) , peripheral cyanosis or Raynaud phenomenon, and superficial thrombophlebitis, often migratory, with indurated red nodules.

RELATED PHYSICAL FINDINGS

Physical examination may reveal cyanotic, ulcerated, or gangrenous, and very painful digits. The dorsalis pedis, posterior tibial, and ulnar pulses are often absent. During episodes of thrombophlebitis, small indurated red, tender nodules will be found, which follow the course of superficial veins and are common on the thigh or calf. Typical changes of Raynaud phenomenon, with well-demarcated pallor or cyanosis of the digits, may be seen on exposure to cold; one or more extremities may be involved. Sensory abnormalities reflecting ischemic neuropathy have been observed in advanced cases. Nail fold examination with capillaroscopy may reveal multiple dilated capillary loops.

Laboratory and Special Tests

There are no specific blood studies. Classical findings on contrast arteriography include segmental occlusions of medium and small blood vessels interspersed with normal appearing wall segments. Corkscrew configuration of collateral vessels originating from the occluded vessels are a classic finding; however, this is non-specific, as it may be seen with other disorders. More proximal and larger caliber vessels are usually spared.

Pathology

In the acute stage, there is a pan-vasculitis of arteries and veins; the diagnostic finding is arterial thrombi with foci of microabscesses and giant cells. In contrast to systemic vasculitis and atherosclerosis, normal architecture is usually well preserved, and there is no early disruption of the internal elastic lamina.[5] In the chronic stage, only fibrotic obliteration of the arteries may be observed. The diagnosis can then only be surmised in the absence of hallmark pathologic changes to support atherosclerosis.

Differential Diagnosis

The same differential diagnoses as for PAD must be considered in thromboangiitis obliterans . In particular, the disease must be distinguished from distal arterial obstructive disease often seen in diabetes mellitus or end-stage chronic kidney disease. Other considerations include autoimmune disease, particularly scleroderma or CREST syndrome (calcinosis cutis, Raynaud phenomenon, esophageal dysfunction, sclerodactyly, and telangiectasia), and ergotamine abuse.

The diagnosis should be considered in young male smokers presenting with symptoms and signs of distal extremity ischemia, migratory thrombophlebitis, or Raynaud phenomenon. An abnormal Allen test (with compromised perfusion of the fingers and blanching secondary to an occluded ulnar artery or incomplete palmar arch following manual compression of the radial artery) in a young smoker with lower extremity ulceration is very suggestive of this disease. The distal nature of disease and associated upper extremity involvement are particularly helpful clues to differentiate from atherosclerotic PAD. Arteriographic findings may support the diagnosis but only biopsy of an artery or vein during the active phase of the disease showing the characteristic pathologic picture is truly diagnostic. Atherosclerosis is the major differential but tends to occur in an older age group, usually more than 45 years of age, and larger vessels

are involved. Raynaud phenomenon is infrequent, and upper extremities are rarely involved. Occasional patients with long-standing diabetes mellitus or end-stage renal disease may exhibit arteriosclerosis affecting medium-sized and distal vessels, but these diagnoses are usually obvious. Raynaud phenomenon associated with scleroderma or CREST syndrome may present with a similar picture, but systemic symptoms, proximal skin changes, and presence of anti-nuclear antibodies will assist in the diagnosis.

Treatment of Thromboangiitis Obliterans

□

IMPROVE BLOOD FLOW

SYMPTOM RELIEF

First line

Smoking cessation

Local wound care
Analgesics

Second line

Anti-platelet agents
Oral vasodilators

Cilostazol (Pletal)
Pentoxifylline (Trental)

Third line

Iloprost
Angioplasty
Surgical endarterectomy or bypass

Sympathectomy
Amputation

Complications

Major clinical complications of this disease include amputation or superimposed infection of ischemic tissue. Rarely, involvement of other vessels may result in myocardial infarction, stroke, or mesenteric ischemia.

Prognosis and Clinical Course

The disease often continues to progress unabated in patients who continue to smoke. Amputations of digits or even extremities may be necessary. The course of the disease is marked by exacerbations and remissions, but usually becomes quiescent after many years. However, in those who manage to quit smoking, remission is common and progression to amputation unusual unless critical limb ischemia with tissue loss is already present. Patients generally have a normal life expectancy.

Treatment

There is no specific treatment other than smoking cessation. Local wound care is imperative, and adequate analgesic therapy is emphasized. In the absence of data from large randomized

trials, anti-platelet agents and vasodilators may play a role and are usually initiated. Similarly, pentoxifylline or cilostazol, both agents used for improving walking distances in claudicants with atherosclerotic disease, may be tried. In one study, daily infusions of iloprost, a prostaglandin analog, were shown to relieve rest pain, heal ulcers, and prevent amputation more frequently than aspirin. Bypass surgery or angioplasty have been reported but are suboptimal therapeutic options because of the small size and distal location of the vessels affected. Sympathectomy may help patients with a prominent vasospastic component. Vascular endothelial growth factor gene therapy may prove of value, but has not been well studied yet.

Prevention

The only preventive measure is never to smoke.