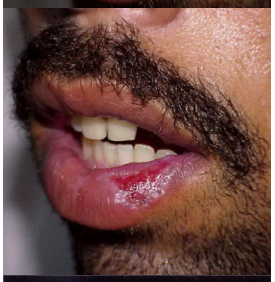

Pseudocarcinomatous hyperplasia = الكاذب السرطاني التصنع فرط

usually seen in the older man. The skin is thickened and rough. It has been considered premalignant.

1 / 1