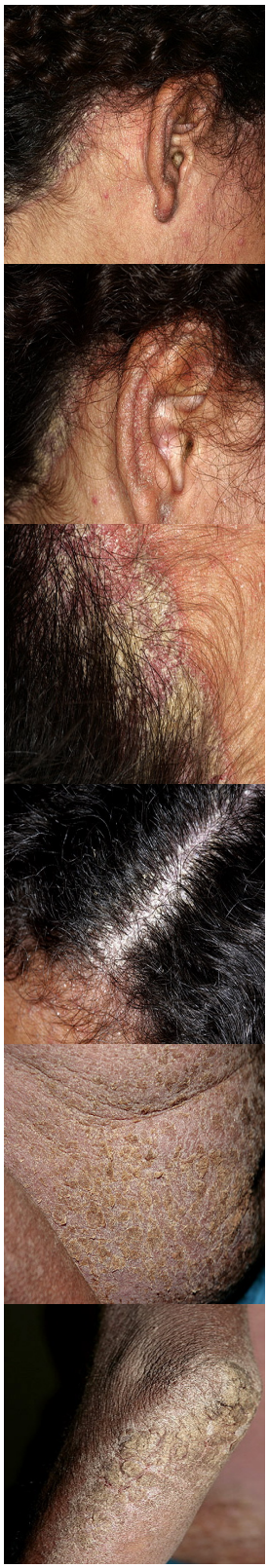

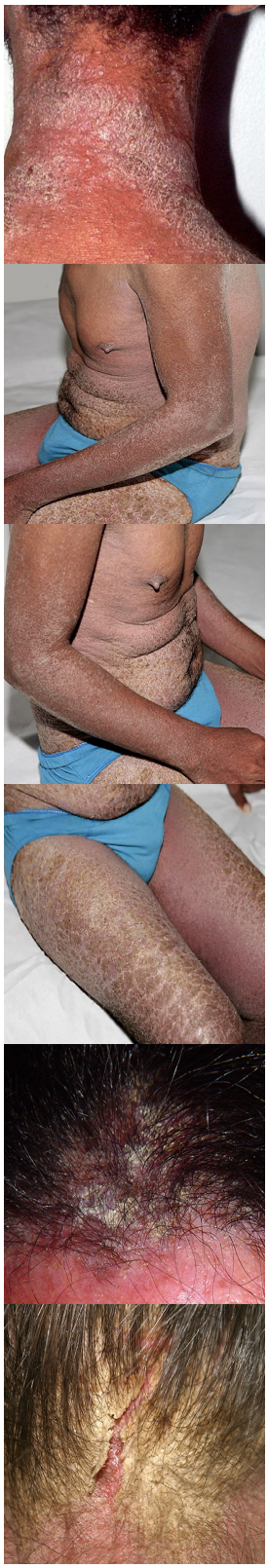

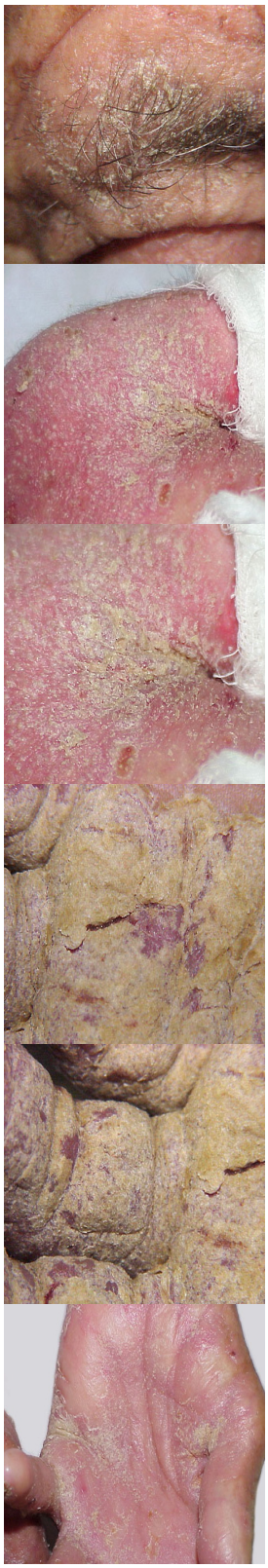

[redacted]

Norwegian scabies, crusted scabies, or hyperkeratotic scabies is a severe form of scabies characterized by profuse, scaly crusts and increasing; [redacted] caused along with topical agents, particularly in crusted c
Corsiner. [redacted] is the crusted variety [redacted]